

September 20, 2023 - Dr. Vogl (wayne.vogl@ubc.ca)

Introduction:

In today's lab we want you to get an overview of the thoracic cavity with special focus on the thoracic wall, the pleural cavities, and the lungs.

Please use the videos to get an overview of this region in the context of the whole body. The 3D scans will help with the 3D relationships of the structures on the anterior and posterior thoracic walls. See the extent of the of the costodiaphragmatic recess. See how the two pleural cavities interact with the mediastinum.

For a conceptual overview, start with the module "Overview of the Thorax", then look at the dissection video and the videos from the Acland atlas. Then look at the photographs and the 3D scans.

Use this module for reference:

Watch this dissection guide video:

Be able to describe (using lecture & module):

- Boundaries of the thoracic inlet and thoracic outlet
- Anatomical and clinical importance of the horizontal plane joining the sternal angle with the T₄ / 5 intervertebral disc
- How to identify the 2nd rib on a patient
- The gross anatomical features of the thoracic walls and lungs

Osteology & Surface Anatomy:

A typical thoracic vertebra (*nb.*
articular facets for the ribs)

Thoracic Vertebra (lateral)

September 20, 2023 - Dr. Vogl (wayne.vogl@ubc.ca)

Sternum:

Manubrium (suprasternal notch, facets for articulation of clavicle and 1st & 2nd ribs)

Manubriosternal joint and the sternal angle (angle of Louis)

Body of sternum (facets for articulation of ribs 2-7)

Xiphoid process (xiphisternum) - *not visible in 3D model*

Ribs:

A typical true rib (head, neck, tubercle, angle, shaft, costal groove)

Costal cartilages

Intercostal spaces

Anterior Ribcage and Sternum

Typical Right Rib

September 20, 2023 - Dr. Vogl (wayne.vogl@ubc.ca)

Muscles: (*module & 3D models*)

Intercostal muscles (as a group)
Diaphragm and its central tendon

Describe the neurovascular contents of an intercostal space:

Arteries & Veins: (*3D anterior thoracic wall*)

Anterior & posterior intercostal arteries and veins
Internal thoracic (mammary) arteries and veins

Nerves:

Intercostal nerves
Phrenic nerves

Be able to describe the course of an intercostal neurovascular bundle and the importance of this for intercostal nerve block and the insertion of chest drains.

Be able to describe the importance of the cervical origin of the phrenic nerves.

September 20, 2023 - Dr. Vogl (wayne.vogl@ubc.ca)

Contents of Intercostal Space

Posterior Thoracic Wall

(B. Kathleen Alsup & Glenn M. Fox,
University of Michigan Medical
School, [BlueLink](#))

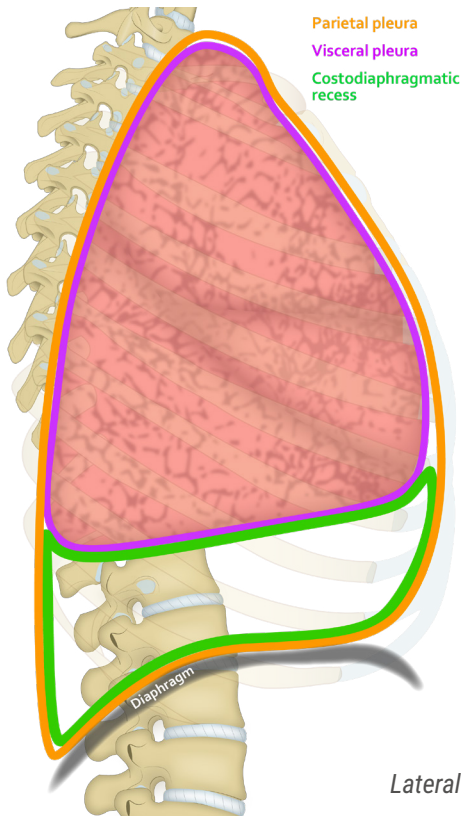
September 20, 2023 - Dr. Vogl (wayne.vogl@ubc.ca)

Lungs in situ

(B. Kathleen Alsup & Glenn M. Fox,
University of Michigan Medical
School, [BlueLink](#))

Suprapleural Membrane:

Be aware of the clinical importance of the pleural cavities rising above the level of the first rib.



Lateral View of Thoracic Pleura

Pleural Cavities: (module)

Visceral & parietal pleura
Costodiaphragmatic recess

September 20, 2023 - Dr. Vogl (wayne.vogl@ubc.ca)

Mediastinum:

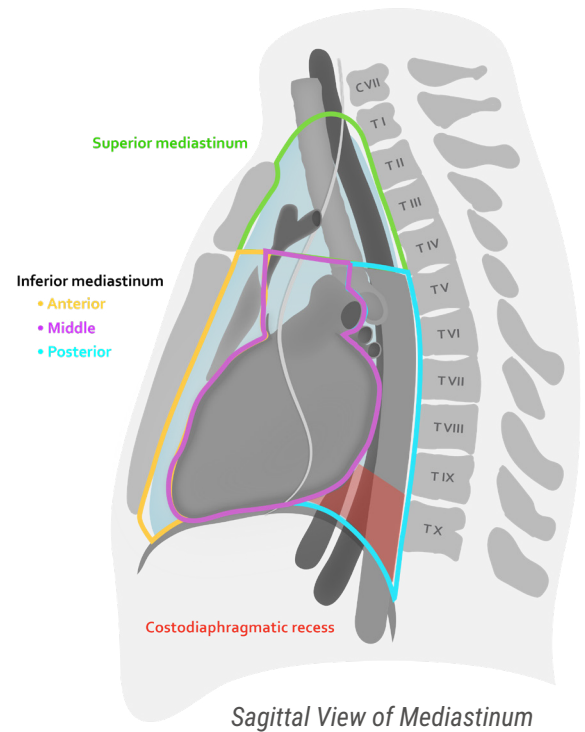
Be able to describe the major anatomical divisions of the mediastinum:

- Superior mediastinum
- Inferior mediastinum (anterior, middle, posterior)

Trachea:

Be able to identify the bifurcation of the trachea and the vertebral level at which this occurs:

Primary (main) & Secondary (lobar) Bronchi



Lungs in situ

(B. Kathleen Alsup & Glenn M. Fox,
University of Michigan Medical
School, [BlueLink](#))

September 20, 2023 - Dr. Vogl (wayne.vogl@ubc.ca)

Links to interactive photographic atlas:

Anterior Thorax (costal cartilage removed)

Lungs:

- Hilum (outlining the root of the lung)
- Fissures (oblique, horizontal/transverse)
- Lobes (upper, middle, lower on right; upper, lower on left)
- Lingula (on left only)

Structures that pass to / from a lung via the hilus / root:

- Pulmonary artery & vein
- Primary bronchus
- Bronchial arteries

September 20, 2023 - Dr. Vogl (wayne.vogl@ubc.ca)

Medial View of Lungs

- Identify the structures in the hilum of the lungs and the anatomy of the lung lobes on the 3D specimens
- Compare the right and left sides

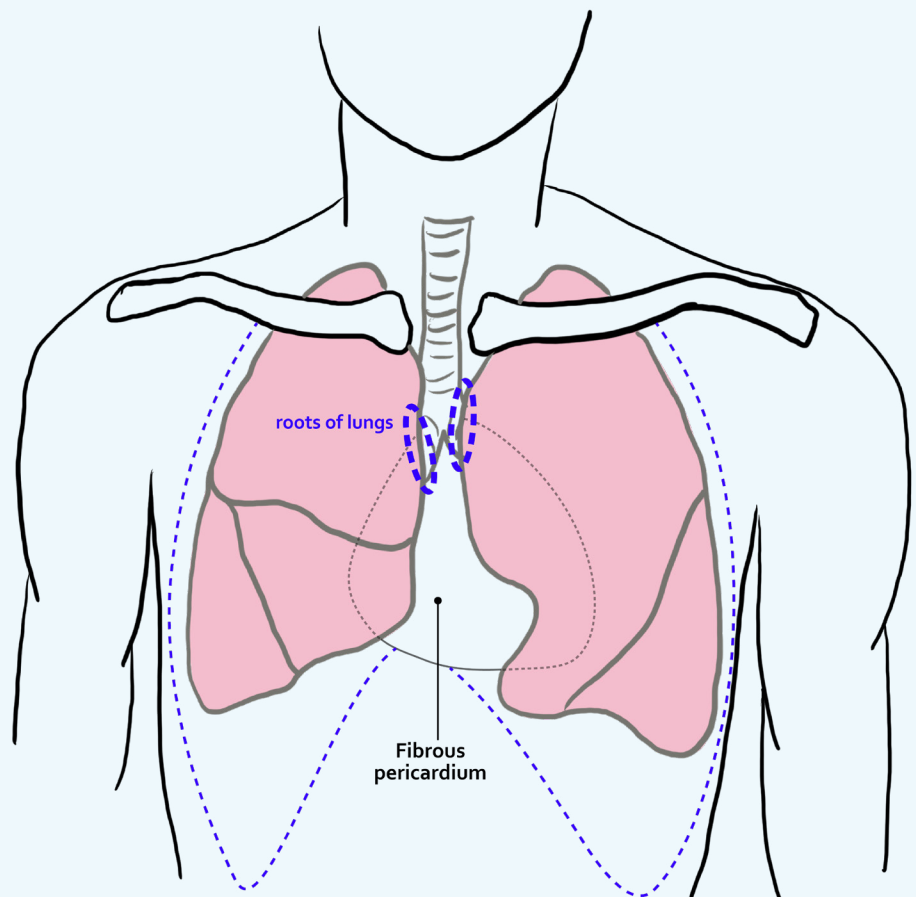
LAB 4 DISSECTOR

September 20, 2023 - Dr. Vogl (wayne.vogl@ubc.ca)

1. Remove the chest plate.
2. Examine intercostal spaces and contents from the posterior. Identify **internal thoracic arteries and veins**.
3. With lungs in place, identify and define the parietal and visceral layers of pleura. Place hand in pleural cavity on each side and define its extent. **Note that pleural cavities (and lungs) rise above the level of the first rib.**
 - Identify the **costodiaphragmatic recess** on each side
4. Identify the 'root' of each lung and pass fingers posteriorly to define its size. Cut through the root of each lung with a scalpel (**see figure**) and, using both hands, carefully remove each lung.
5. Identify the fissures and lobes of each lung and examine the major components of the roots (pulmonary A. and V., primary bronchus).
6. With the lungs removed, examine the extent of each pleural cavity and reflect some parietal (costal) pleura from the posterior chest wall. Also identify and dissect out the phrenic nerves.

Note the greater and lesser splanchnic nerves.

7. Replace lungs and chest plate at the end of the lab.



Anterior view showing incision locations at root of each lung (step 4)