

October 11, 2023 - Dr. Doroudi (majid.doroudi@ubc.ca)

Introduction:

Welcome to this lab on the anatomy of the superior and posterior mediastinum. The objectives of this lab (details in each section) are as follows:

- Describe the divisions of the mediastinum and their contents
- Discuss the clinical importance of the portocaval anastomosis found in the lower part of the esophagus
- Describe the course of the thoracic duct
- Describe the course and anatomical relationships of the esophagus
- Describe the clinical importance of the diameter and orientation of the trachea and the main bronchi
- Identify the big vessels in the superior mediastinum
- Describe the relationship of the great vessels entering and leaving the heart
- Describe the origin, course and function of the phrenic nerves

Superior Mediastinum

Identify and examine:

Tracheal bifurcation into left and right primary (main) bronchi

Be able to describe the clinical importance of the different sizes and courses of the left and right primary bronchi.

Arteries:

- Arch of aorta
- Brachiocephalic trunk (artery)
- Common carotid artery (L & R)
- Subclavian artery (L & R)
- Pulmonary trunk
 - Pulmonary artery (L & R)

Veins:

- Superior vena cava
- Arch of azygos vein
- Brachiocephalic vein (L & R)
- Internal jugular vein (L & R)
- Subclavian vein (L & R)

Ductus Arteriosus/ Ligamentum Arteriosum

October 11, 2023 - Dr. Doroudi (majid.doroudi@ubc.ca)

Superior Mediastinum

Nerves:

Left & right vagus nerves (and their course)

Left & right phrenic nerves (origin, course and function)

- be aware of the clinical importance of the cervical origin of the phrenic nerves

Left & right recurrent laryngeal nerves

- be aware of the importance of the intrathoracic course of the left recurrent laryngeal nerve

Why can pathology in the thorax present as a change in voice?

October 11, 2023 - Dr. Doroudi (majid.doroudi@ubc.ca)

Superior Mediastinum:

B. Kathleen Alsup & Glenn M. Fox, University of Michigan Medical School, [BlueLink](#)

Superior Mediastinum

October 11, 2023 - Dr. Doroudi (majid.doroudi@ubc.ca)

Superior Mediastinum

Images: B. Kathleen Alsup & Glenn M. Fox, University of Michigan Medical School, [BlueLink](#)

Design & Artwork: The HIVE (hive.med.ubc.ca)

October 11, 2023 - Dr. Doroudi (majid.doroudi@ubc.ca)

Posterior Mediastinum

Thoracic splanchnic nerves

Descending (thoracic) aorta

Azygos system of veins

Thoracic duct (between descending aorta & azygos vein)

Posterior intercostal arteries, veins & nerves

Esophagus

- ***The course and anatomical relationships of the esophagus in the thorax***
- ***Be aware of the diagnostic importance of the relationship of the esophagus with the arch of the aorta, the left primary (main) bronchus and the left atrium***

Posterior Mediastinum

October 11, 2023 - Dr. Doroudi (majid.doroudi@ubc.ca)

Contents of Intercostal Space

Posterior Thoracic Wall

(B. Kathleen Alsup & Glenn M. Fox,
University of Michigan Medical
School, [BlueLink](#))

October 11, 2023 - Dr. Doroudi (majid.doroudi@ubc.ca)

Neurovasculature of Posterior Thoracic Wall

Posterior Thoracic Wall
(B. Kathleen Alsup & Glenn M. Fox,
University of Michigan Medical
School, [BlueLink](#))

Neurovasculature of Posterior Thoracic Wall

Be able to describe:

- The course and major relationships of the great vessels entering and leaving the heart
- The **vertebral levels** at which the following pierce the diaphragm to enter or leave the thoracic cavity:

Inferior vena cava

Esophagus

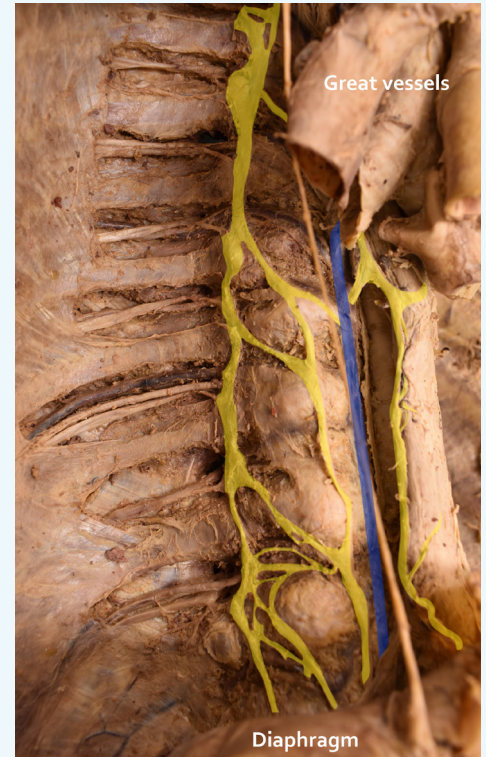Descending thoracic aorta

LAB 6 DISSECTOR

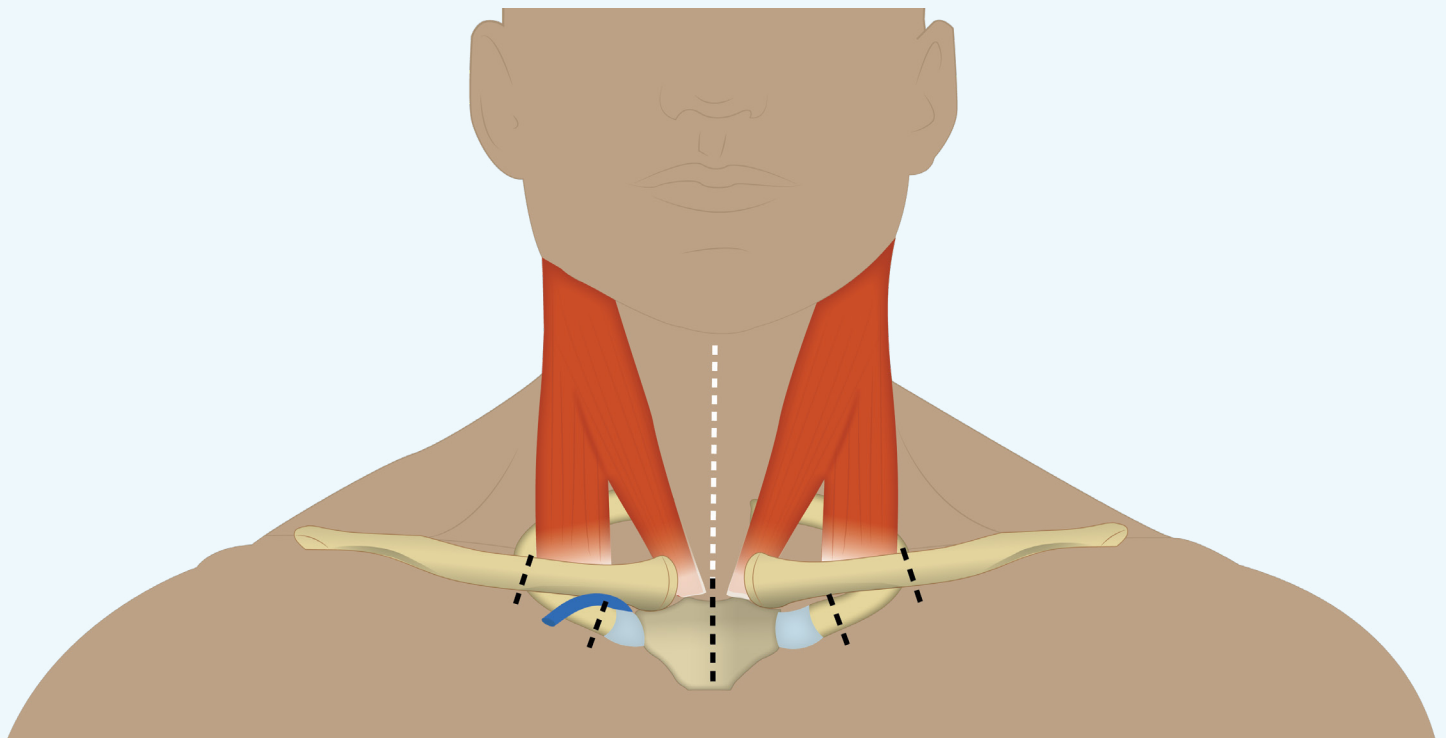
October 11, 2023- Dr. Doroudi (majid.doroudi@ubc.ca)

Dissection to Expose Structures in the Superior Mediastinum

1. Cut through the skin of the lower half of the neck (as indicated by white line).
2. Saw through the medial third of each clavicle and first rib (preserving the subclavian veins).
3. Saw through the middle of the manubrium.
4. Retract the remains of the manubrium superiorly.



Splanchnic nerves and azygos vein on posterior thoracic wall



Dissection of the superior mediastinum (steps 1 - 2)