

January 17, 2024 - Kurt McBurney ([mcburney@uvic.ca](mailto:mcburney@uvic.ca))

### **Objectives:**

1. Identify the roots, trunks and cords of the brachial plexus.
2. Identify the radial, axillary, musculocutaneous, median and ulnar nerves.
3. Identify the muscles or skin areas supplied by the major branches of the brachial plexus.
4. Identify the axillary artery and the relationship of brachial plexus cords to the vessel.

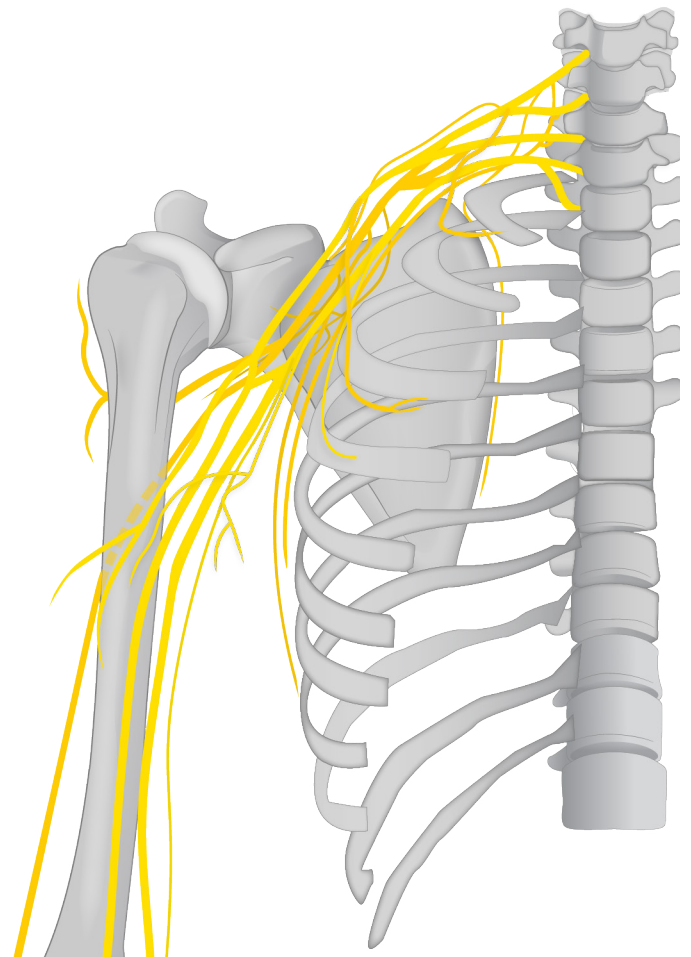
### **Be able to describe:**

- What parts of a spinal nerve contribute to somatic plexuses in the body
- Which body regions are innervated by somatic plexuses
- The relationship of the axillary artery to the brachial plexus
- The general position and shape of the axilla and define the boundaries of the inlet

### **3D Specimens:**

### **Modules:**

### **Videos:**



January 17, 2024 - Kurt McBurney ([mcburney@uvic.ca](mailto:mcburney@uvic.ca))

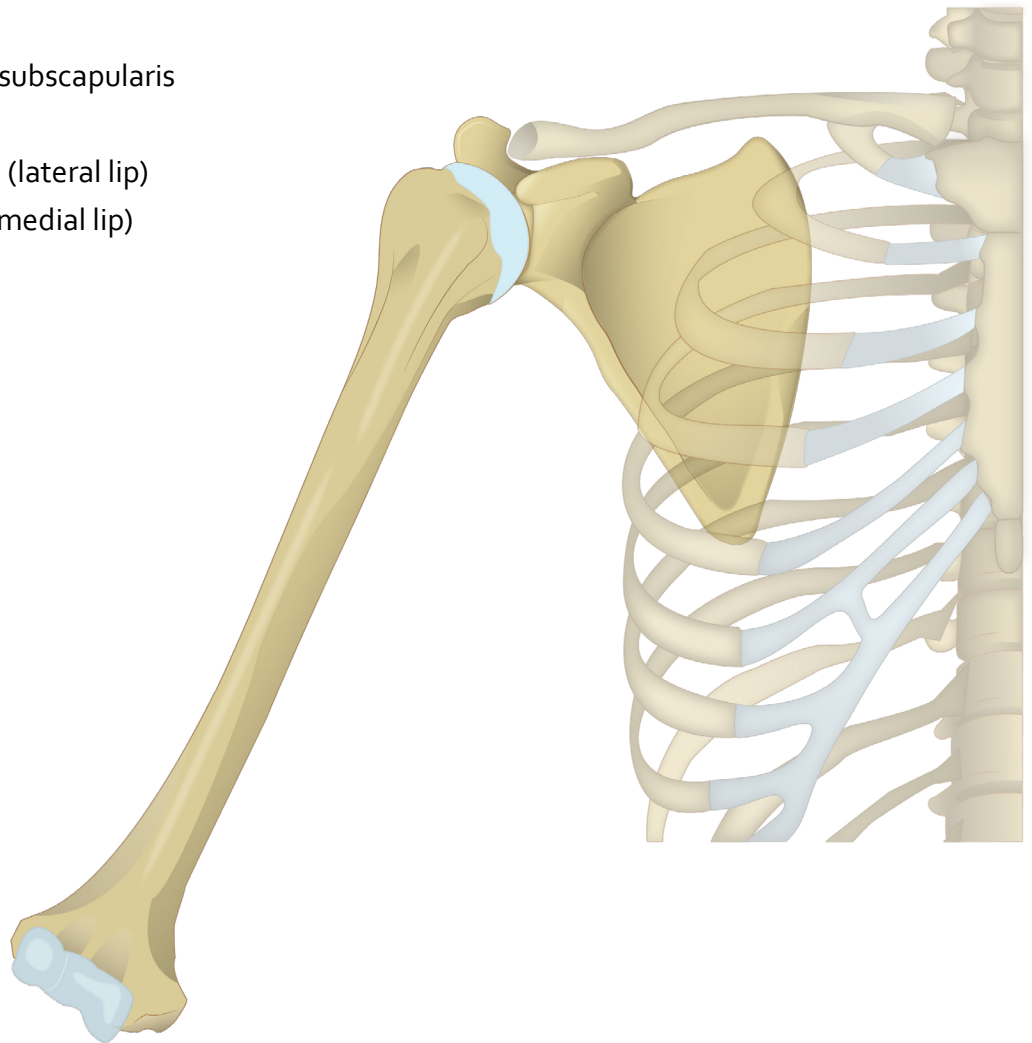
**Identify the following bony structures:**

## Scapula

- Subscapular fossa
- Coracoid process
- Glenoid cavity
- Suprascapular notch
- Supra- and Infra-glenoid tubercles

## Proximal Humerus

- Head
- Anatomical neck
- Surgical neck
- Greater tubercle
  - Facets for attachment of supraspinatus, infraspinatus, teres minor
- Lesser tubercle
  - Facet for attachment of subscapularis
- Intertubercular sulcus
  - Crest of greater tubercle (lateral lip)
  - Crest of lesser tubercle (medial lip)
- Deltoid tuberosity



January 17, 2024 - Kurt McBurney ([mcburney@uvic.ca](mailto:mcburney@uvic.ca))

***Be able to describe and identify the major components of the brachial plexus:***

Roots and trunks

Medial, lateral and posterior cords

The following terminal nerves:

Long thoracic

Musculocutaneous

Median

Radial

Ulnar

Axillary

*Nerves of the Brachial Plexus*

January 17, 2024 - Kurt McBurney ([mcburney@uvic.ca](mailto:mcburney@uvic.ca))

*Root of Neck (Anterior)*

B. Kathleen Alsup & Glenn M. Fox, University  
of Michigan Medical School, [BlueLink](#)

*Axillary Artery and M Landmark*



January 17, 2024 - Kurt McBurney ([mcburney@uvic.ca](mailto:mcburney@uvic.ca))

## Veins

### *Deep:*

Subclavian

Axillary

### *Superficial:*

Cephalic

Basilic

Median cubital

### *Superficial Veins (Anterior)*

B. Kathleen Alsup & Glenn M. Fox, University  
of Michigan Medical School, [BlueLink](#)

January 17, 2024 - Kurt McBurney ([mcburney@uvic.ca](mailto:mcburney@uvic.ca))

## Muscles

- Subscapularis (rotator cuff)
- Long & short heads of biceps
- Brachialis
- Coracobrachialis
- Long head of triceps
- Latissimus dorsi
- Teres major

**Note:** The other muscles of the rotator cuff (supraspinatus, infraspinatus, teres minor) were covered in the Back & Posterior Scapular Region Lab in MEDD 411.

*Superficial Arm (Anterior)*

B. Kathleen Alsup & Glenn M. Fox, University of Michigan Medical School, [BlueLink](#)

January 17, 2024 - Kurt McBurney ([mcburney@uvic.ca](mailto:mcburney@uvic.ca))

## Arteries

Axillary

Anterior & posterior  
humeral circumflex

Profunda brachii

Brachial

*Deep Arm (Anterior)*

B. Kathleen Alsup & Glenn M. Fox, University  
of Michigan Medical School, [BlueLink](#)

January 17, 2024 - Kurt McBurney ([mcburney@uvic.ca](mailto:mcburney@uvic.ca))

## Spaces

Quadrangular space

Triangular interval

*Posterior Shoulder and Arm*

January 17, 2024 - Kurt McBurney ([mcburney@uvic.ca](mailto:mcburney@uvic.ca))

*Shoulder & Arm (Posterior)*

B. Kathleen Alsup & Glenn M. Fox, University  
of Michigan Medical School, [BlueLink](#)

January 17, 2024 - Kurt McBurney ([mcburney@uvic.ca](mailto:mcburney@uvic.ca))

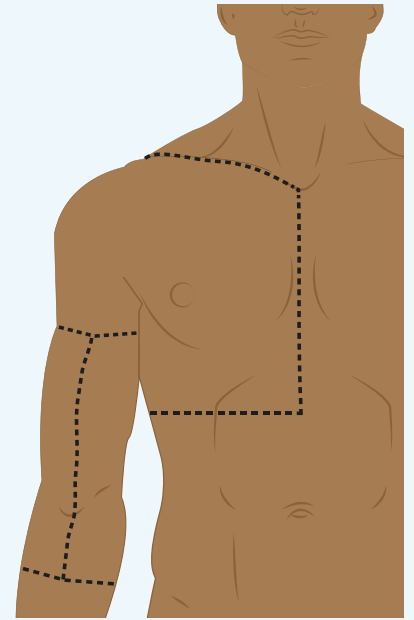
*Shoulder & Arm (Posterior)*

B. Kathleen Alsup & Glenn M. Fox, University of Michigan Medical School, [BlueLink](#)

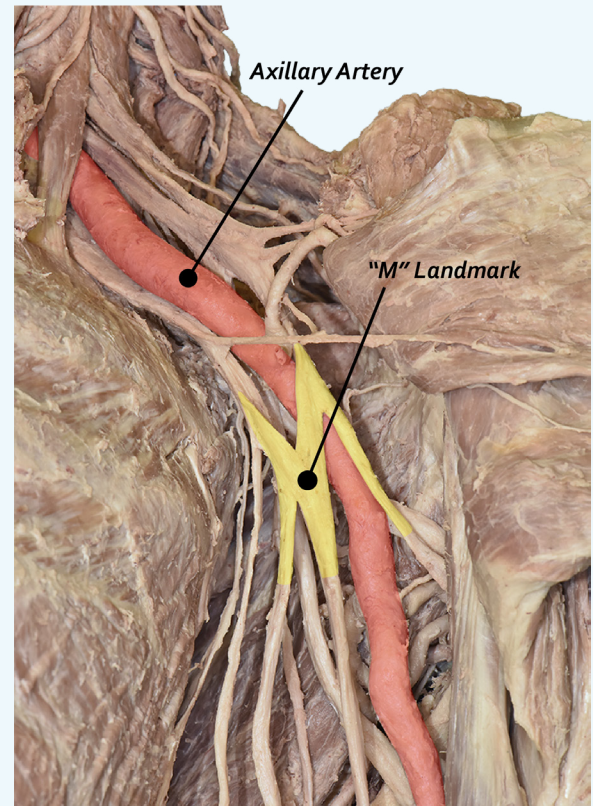
# LAB 2 DISSECTOR

January 17, 2024 - Kurt McBurney ([mcburney@uvic.ca](mailto:mcburney@uvic.ca))

- 1. Remove skin from the arm and the forearm down to the junction between the proximal and middle thirds of the forearm as shown in the diagram.**
  - Identify the cephalic and basilic veins and try to leave them in position when removing subcutaneous fascia to expose the deep fascia.
  - Leave the deep fascia in the forearm intact.
- 2. Reflect pectoralis major and cut pectoralis minor from its attachment to ribs.**
  - Identify the axillary sheath surrounding the neurovascular bundle in the axilla and carefully begin to probe through the anterior aspect of the sheath and expose and identify the axillary vein.
  - Identify the cephalic vein and identify where the axillary vein becomes the subclavian vein.
- 3. Remove the axillary vein and identify the axillary artery and related nerves.**
  - Identify the coracobrachialis muscle, the long and short heads of biceps brachii muscle, and the brachialis muscle.
  - Identify the lateral and medial cords of the brachial plexus.
  - Identify the musculocutaneous nerve that penetrates coracobrachialis and identify the nerve as it continues between the biceps brachii and brachialis muscle.
  - Identify the contributions of the lateral cord and medial cord to the median nerve.
  - Identify the ulnar nerve.
- 4. Together, the medial and lateral cords, the musculocutaneous nerve, the median nerve and the ulnar nerve form an 'M' anterior to the brachial artery. The easiest way to identify the 'M' is to identify the musculocutaneous nerve first, which is the lateral arm of the 'M', and work medially to the ulnar nerve.**



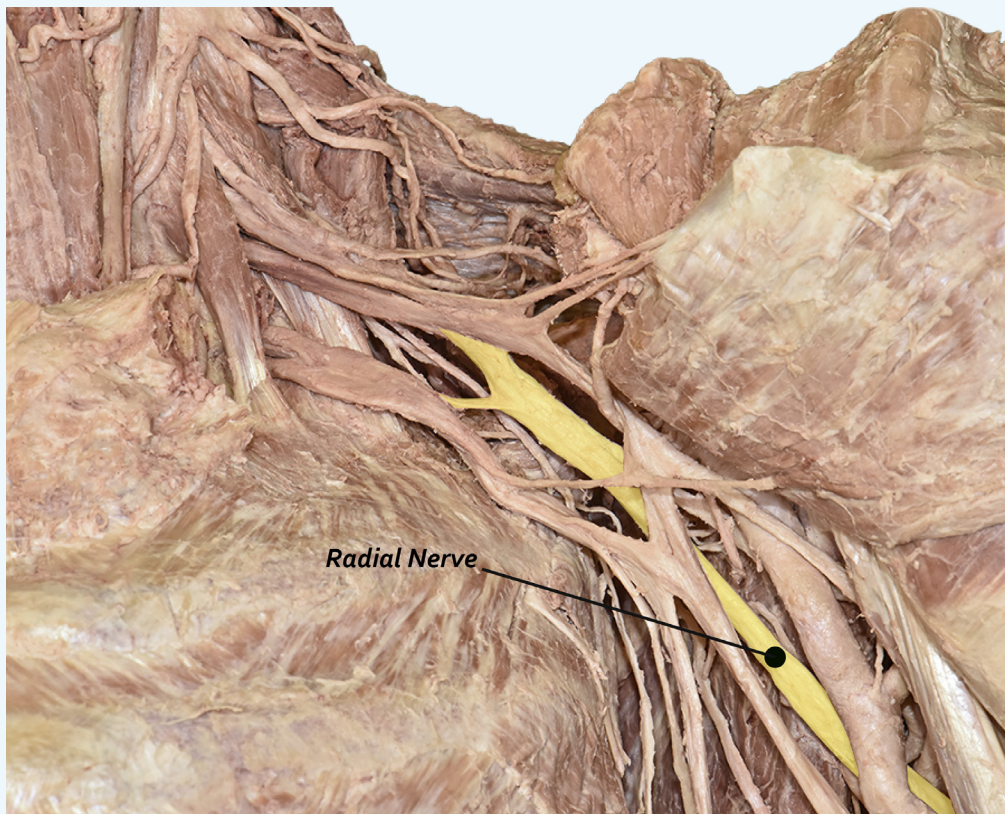
**Dissection lines for steps 1 through 2**



# LAB 2 DISSECTOR

January 17, 2024 - Kurt McBurney ([mcburney@uvic.ca](mailto:mcburney@uvic.ca))

5. *In the axilla, move the axillary artery and related nerves medially and identify the posterior cord of the brachial plexus.*
  - Identify the radial nerve which is the continuation of the posterior cord, and the important axillary nerve
  
6. *In the posterior wall of the axilla:*
  - Identify the subscapularis muscle, the teres major muscle, and the tendon of latissimus dorsi muscle.
  - Identify the long head of triceps
  - Identify the quadrangular space (defined laterally by the humerus, medially by the long head of triceps, superiorly by the subscapularis, and inferiorly by teres major)
  - Identify the triangular interval (defined laterally by the humerus, medially by the long head of triceps, and superiorly by the teres major)
  - Identify the axillary nerve and posterior circumflex humeral artery in the quadrangular space.
  - Identify the radial nerve and the profunda brachii artery coursing through the triangular interval to get into the posterior compartment of the arm





# LAB 2 DISSECTOR

January 17, 2024 - Kurt McBurney ([mcburney@uvic.ca](mailto:mcburney@uvic.ca))

7. *Identify muscles in the anterior compartment of the arm:*

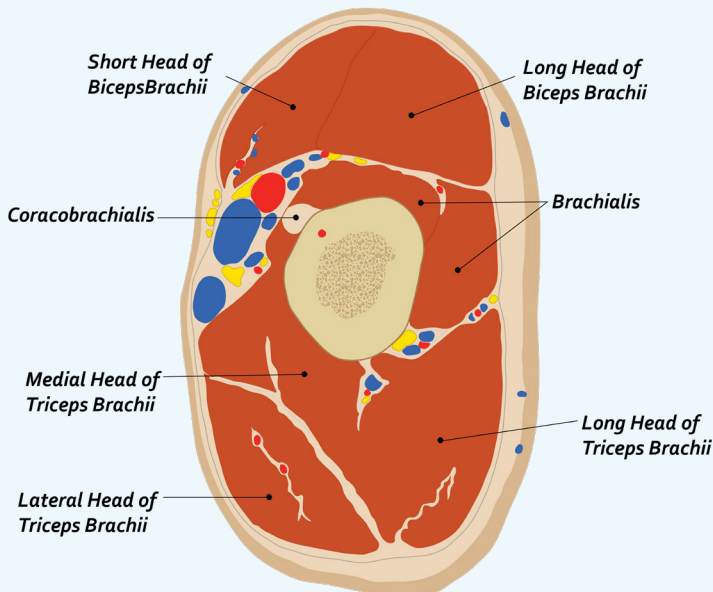
- Coracobrachialis, biceps brachii (long and short heads) and brachialis.

8. *On the medial side of the arm:*

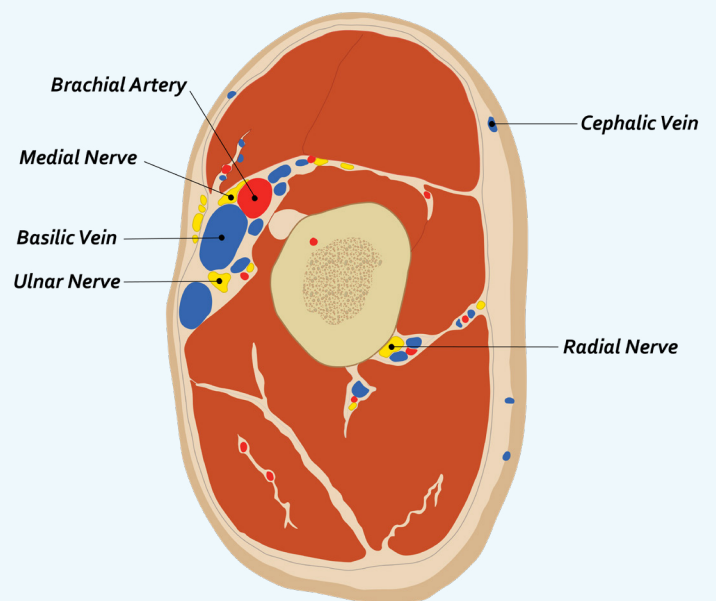
- Identify the brachial artery and the profunda brachii artery.
- Identify the median nerve and ulnar nerve and follow them distally to just above the elbow.

9. *On the lateral side of the arm:*

- Identify the brachioradialis muscle originating from the supracondylar ridge of the humerus and gently reflect it away from deeper muscles to find the radial nerve.
- Identify the supinator muscle. (*Only remove enough of the deep fascia to free the margin of the brachioradialis muscle.*)
- Identify the musculocutaneous nerve between biceps brachii and brachialis, and follow the nerve as it becomes cutaneous in the distal region of the arm.



**Cross Section of Arm Muscles  
(Right Arm - Superior View)**

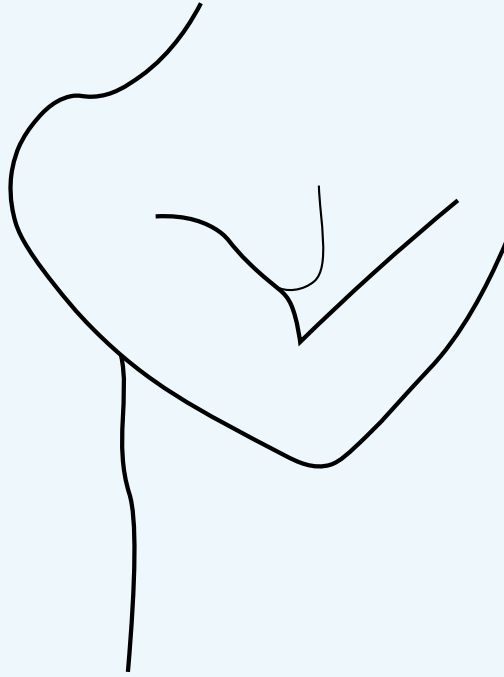


**Cross Section of Arm Vessels and Nerves  
(Right Arm - Superior View)**

# LAB 2 DISSECTOR

January 17, 2024 - Kurt McBurney ([mcburney@uvic.ca](mailto:mcburney@uvic.ca))

10. When finished with the anterior compartment of the arm, flex the arm over the chest as shown in the figure and identify the triceps brachii, which is the only muscle in the posterior compartment of the arm.



***Flex the arm over the chest (step 10)***

- Identify the long and lateral heads of the muscle.
- Identify the radial nerve as it appears deep to the brachioradialis muscle in the distal arm and then place a probe along the course of the nerve deep to the lateral head of triceps brachii and towards the triangular interval between the lower border of teres major muscle, the long head of triceps brachii and the medial margin of the humerus.
- **Very carefully** cut the lateral head of the triceps along the course of the probe and reflect the upper part of the muscle to reveal the radial nerve and profunda brachii artery that lie in the radial groove on the posterior surface of the humerus.
- At this point, you should also be able to identify the medial head of triceps brachii that originates from the posterior surface of the humerus below the level of the radial groove.
- Identify the attachment of the triceps tendon to the olecranon of the ulna.

11. When finished the dissection, wrap the limb with moist material and cover with a plastic bag.