

February 6, 2024 - Dr. Krebs (claudia.krebs@ubc.ca)

Objectives:

- Identify the location of the pelvic viscera to their peritoneal coverings
- Recognize the significance of the orientation of the uterus and its variations
- Describe the importance of the ligaments that support the uterus during pregnancy, childbirth and aging
- Apply the topographical anatomy of vessels and nerves in the pelvis and perineum to clinical situations
- Recognize the anatomy of the perineum as it relates to childbirth

Videos:

(requires CWL login)

Volume 5 - Reproductive System

- 5.3.5 Muscles of the perineum
- 5.3.8 Uterus
- 5.3.9 Uterine tubes
- 5.3.10 Clitoris, external genitalia
- 5.3.11 Clitoris, vagina
- 5.2.13 Rectum
- 5.2.31 Bladder female

3D Models:

Modules:

Pelvic Bones

Coccyx

Sacrum

Hip (pelvic) bone

Acetabulum

Ischiopubic (pubic) arch

Obturator foramen

Ilium

- Anterior superior iliac spine

- Crest

- Iliac fossa

Ischium

- Spine

- Tuberosity

Pubis

- Tubercle

- Crest

- Pubic symphysis

Anterior view of android pelvis

February 6, 2024 - Dr. Krebs (claudia.krebs@ubc.ca)

Ligaments

- Sacrospinous
- Sacrotuberous

Muscles

- Levator ani

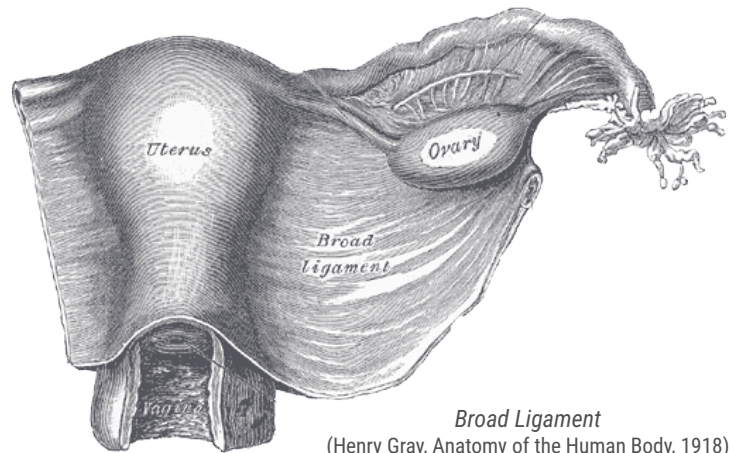
Be able to define:

- Greater sciatic foramen
- Lesser sciatic foramen

Peritoneum

- Rectouterine pouch
- Broad ligament
 - Mesosalpinx
 - Mesovarium
 - Mesometrium
- Ovarian ligament
- Suspensory ligament of ovary
- Round ligament of uterus

Lateral view of pelvis



Broad Ligament
(Henry Gray, Anatomy of the Human Body, 1918)

Anterior view of female reproductive organs

February 6, 2024 - Dr. Krebs (claudia.krebs@ubc.ca)

Female Pelvic Cavity

(B. Kathleen Alsup & Glenn M. Fox, University of Michigan Medical School, [BlueLink](#))

February 6, 2024 - Dr. Krebs (claudia.krebs@ubc.ca)

Viscera

Rectum

Urinary bladder

Urethra

Ureter

Uterus

- Fundus

- Body

- Cervix

Ovaries

Sagittal section of female pelvis

Sagittal Section of Female Pelvis
B. Kathleen Alsup & Glenn M. Fox, University
of Michigan Medical School, [BlueLink](#))

February 6, 2024 - Dr. Krebs (claudia.krebs@ubc.ca)

Arteries

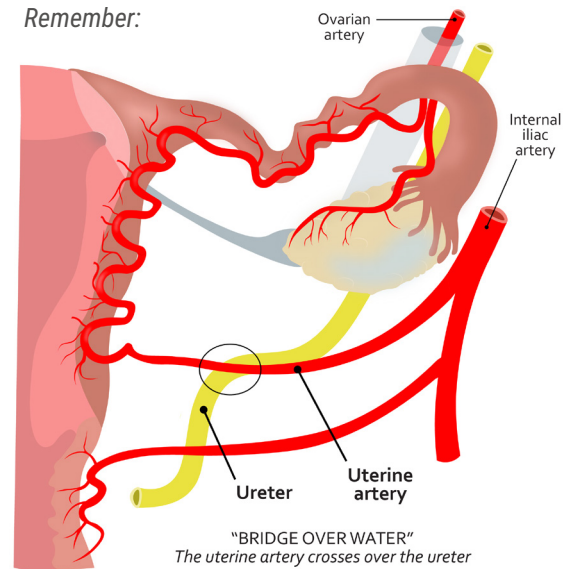
Internal iliac
- Uterine

Nerves

Pudendal

Antero-inferior View of Female Perineum
(B. Kathleen Alsup & Glenn M. Fox, University of Michigan Medical School, [BlueLink](#))

Remember:



Sagittal Section of Female Pelvis
(B. Kathleen Alsup & Glenn M. Fox, University of Michigan Medical School, [BlueLink](#))

February 6, 2024 - Dr. Krebs (claudia.krebs@ubc.ca)

Perineum

Anal triangle

Urogenital triangle

Female Perineum - Inferior View

(B. Kathleen Alsup & Glenn M. Fox, University of Michigan Medical School, [BlueLink](#))

Anal Triangle

Levator ani

External anal sphincter

Pudendal nerve

Internal pudendal artery & vein

Urogenital Triangle

Perineal membrane (*describe position of deep perineal pouch*)

Superficial perineal pouch:

- Corpus cavernosum
- Clitoris
- Ischiocavernosus muscle
- Bulb of the vestibule
- Bulbospongiosus muscle
- Superficial transverse perineal muscle
- Pudendal nerve

Vagina

Urethra

Inferior view of female perineum

February 6, 2024 - Dr. Krebs (claudia.krebs@ubc.ca)

Antero-inferior view of female perineum

(B. Kathleen Alsup & Glenn M. Fox, University of Michigan Medical School, [BlueLink](#))

Inferior view of female perineum

February 6, 2024 - Dr. Krebs (claudia.krebs@ubc.ca)

RESOURCES

Websites:

Clinical Anatomy | Entrada

Recommended Textbooks:

Gray's Anatomy for Students

By: Drake, Vogl, Mitchell

Elsevier Inc. Churchill Livingstone

ISBN 978-0-7020-5131-9

** OR **

Essential Clinical Anatomy

By: Moore and Agur

Lippincott Williams & Wilkins

ISBN 0-7817-6274-X

One of the Following Atlases:

Gray's Atlas of Anatomy

By: Drake, Vogl, Tibbits, Richardson, Mitchell

Elsevier

ISBN 978-1-4557-4802-0

Atlas of Anatomy

By: Gilroy, MacPherson, Ross

Thieme

ISBN 978-1-60406-062-1

Atlas of Human Anatomy

By: Frank Netter

Icon Learning Systems

ISBN 1-929007-11-6

Before We Are Born

By: Moore and Persaud

Saunders

ISBN 978-1-4160-3705-7

ACKNOWLEDGEMENTS

Artwork & Design:

The HIVE, UBC Faculty of Medicine

Instructional Design: Monika Fejtek

Medical Illustration Lead: Paige Blumer

Academic Lead: Claudia Krebs

Prosector: Lien Vo

